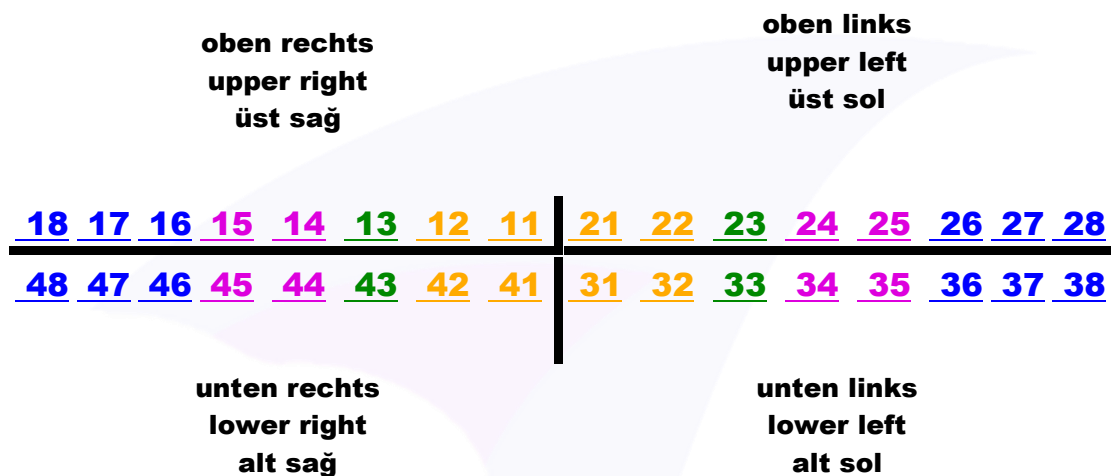
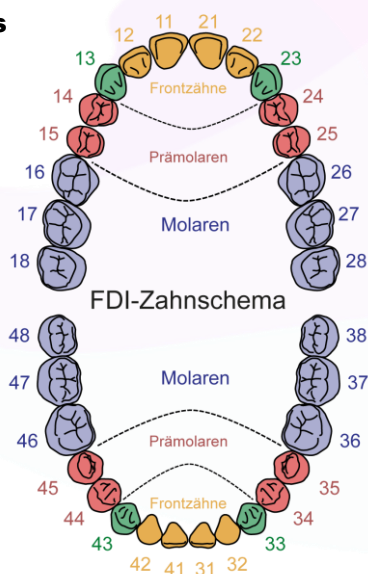
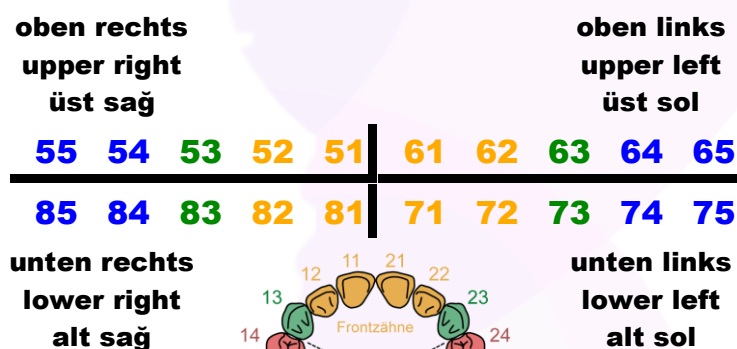


FDI-Zahnschema (nach Viohl)



Milchzahngebiss Primary Dentition Süt Dentisyon



Incisivi (Schneidezähne)	Canini (Eckzähne)	Prämolaren (Vormahlzähne)	Molaren (Mahlzähne)
Incisor	Canine	Premolar	Molar
Kesici	Köpek	Küçük azı	Azı